

Original Article

Comparison of the offset distance of the tricuspid septal leaflet in neonates with Ebstein's anomaly and neonates with pulmonary atresia with intact ventricular septum

Min Jeong Kim, Jeong Jin Yu, So Yeon Kang, Chang Deok Seo, Jae Suk Baek, Young-Hwue Kim, Jae-Kon Ko

Division of Pediatric Cardiology, College of Medicine, University of Ulsan, Songpa-gu, Seoul, South Korea

Abstract An indexed offset distance of the tricuspid septal leaflet $\geq 8 \text{ mm/m}^2$ is a quantitative criterion for the diagnosis of Ebstein's anomaly. The purpose of this study was to investigate the validity of this criterion for the discrimination of Ebstein's anomaly from pulmonary atresia with intact ventricular septum in neonatal patients. A total of 122 neonatal patients, 56 with Ebstein's anomaly and 66 with pulmonary atresia with intact ventricular septum, were enrolled. Diagnosis of each anomaly was based on typical morphologic features. Echocardiographic variables, including the offset distance of the tricuspid septal leaflet, were measured via an offline analysis of images recorded before 1 month of age. The offset distance of the tricuspid septal leaflet was indexed by the body surface area, and the indexed offset distances in the Ebstein's anomaly and pulmonary atresia with intact ventricular septum groups were 34.2 mm/m^2 (7.1–119.1 mm/m^2) and 7.2 mm/m^2 (0.0–25.6 mm/m^2), respectively. The indexed offset distance was $\geq 8 \text{ mm/m}^2$ in 29 (43.9%) of the patients with pulmonary atresia with intact ventricular septum; clinical and echocardiographic characteristics were comparable between these 29 patients and the remaining 37 patients with pulmonary atresia with intact ventricular septum. When an indexed offset distance $\geq 8 \text{ mm/m}^2$ was applied as a cut-off for the diagnosis of Ebstein's anomaly, the sensitivity was 0.963 and the specificity was 0.561. In conclusion, indexed offset distance $\geq 8 \text{ mm/m}^2$ cannot be used as a cut-off for the diagnosis of complicated Ebstein's anomaly in neonatal patients with pulmonary atresia with intact ventricular septum.

Keywords: Ebstein's anomaly; pulmonary atresia; newborn; echocardiography

Received: 31 January 2014; Accepted: 19 June 2014; First published online: 15 July 2014

EBSTEIN'S ANOMALY IS A RARE CONGENITAL HEART malformation that accounts for <1% of all congenital heart disease cases.¹ Despite its low rate of occurrence, neonatal presentation of Ebstein's anomaly is associated with a high incidence of mortality. Before the year 2000, the mortality rate of affected neonates ranged from 26 to 81%.^{2,3} Although management of the disease and its outcomes has been improving,^{3–5} management of neonates with symptomatic Ebstein's anomaly is still challenging.^{6,7} Pulmonary atresia, an associated

complication, is a significant predictor of poor outcomes in neonates with Ebstein's anomaly.^{2–4,7} Similarly, concurrent occurrence of Ebstein's anomaly in patients with pulmonary atresia with intact ventricular septum, which occurs at a rate of 8–9.8% in these patients, is a significant predictor of poor outcomes.^{8,9} Therefore, a confirmative diagnosis of Ebstein's anomaly is important for optimising the treatment and management of neonates diagnosed with pulmonary atresia with intact ventricular septum.

A prominent apical displacement of the septal leaflet of the tricuspid valve from the atrioventricular junction is an intrinsic morphologic feature of Ebstein's anomaly. An indexed offset distance of the tricuspid septal leaflet $\geq 8 \text{ mm/m}^2$ has been used or

Correspondence to: J. J. Yu, MD, Asan Medical Center, Division of Pediatric Cardiology, 88 Olympic-ro 43-gil, Songpa-gu, Seoul 138-736, South Korea. Tel: +8 223 010 3924; Fax: +822 473 3725; E-mail: pediatrist@medimail.co.kr

suggested as a diagnostic criterion of Ebstein's anomaly in multiple studies and reviews^{10–17} after it was first reported by Shiina et al in 1984,¹⁸ although an overlap of the minimal septal offset distance between the cases with and without Ebstein's anomaly was reported in the same year by other authors.¹⁹ To the best of our knowledge, this criterion has not yet been reviewed comprehensively in neonatal populations. Therefore, the purpose of this study was to investigate the discriminative validity of the indexed offset distance of the tricuspid septal leaflet as a criterion for the diagnosis of Ebstein's anomaly in neonatal patients previously diagnosed with this malformation or pulmonary atresia with intact ventricular septum.

Materials and methods

Patients

Between January, 2001 and June, 2013, 66 neonates with Ebstein's anomaly and 80 neonates with pulmonary atresia with intact ventricular septum were managed in the Division of Pediatric Cardiology at the Asan Medical Center (Seoul, South Korea). Diagnosis of these patients was based on typical morphologic features identified through echocardiography. For Ebstein's anomaly, an apical displacement of the septal and inferior leaflets of the tricuspid valve and the existence of an atrialised right ventricle were essential diagnostic features. Incomplete delamination of the anterior tricuspid leaflet is also an important feature of Ebstein's anomaly; therefore, patients compatible with the above definition of Ebstein's anomaly have this feature diagnosed, regardless of pulmonary atresia. Pulmonary atresia with intact ventricular septum was defined as anatomic pulmonary atresia without any other major cardiac anomalies, except atrial septal defect, patent ductus arteriosus, and coronary fistulae. Patients with abnormal atrial situs or abnormal connections of cardiac segments, including a corrected transposition of the great arteries were excluded from the study. Of the 146 patients examined, 24 patients were excluded because of issues related to the echocardiographic images collected from neonates in the first 30 days after birth; specifically, postnatal echocardiographs were absent for two patients, some images were omitted for 12 patients, and poor quality images, on which offline analyses were not possible, were collected for 10 patients. A total of 122 residual patients were enrolled: 56 patients had Ebstein's anomaly and 66 patients had pulmonary atresia with intact ventricular septum. Additional cardiac anomalies with Ebstein's anomaly were pulmonary atresia in seven, pulmonary stenosis in three, ventricular septal defects in 5, juxtaposition of the right

atrial appendage in one, and non-compaction of left ventricle in three patients. Of the patients with Ebstein's anomaly, 20 had functional atresia of pulmonary valve. Major right ventricular-dependent coronary circulation was identified in four patients with pulmonary atresia with intact ventricular septum. Bicuspid aortic valve was found in one patient with pulmonary atresia with intact ventricular septum. Of the patients, seven with Ebstein's anomaly and pulmonary atresia were only included in the Ebstein's anomaly group, not in the pulmonary atresia with intact ventricular septum group. Wolff-Parkinson-White syndrome was diagnosed in two patients with Ebstein's anomaly.

Clinical variables were investigated through a review of medical records. Anthropometric data collected on the same day on which the echocardiographic examination was conducted were selected. Body surface area was calculated using the Haycock formula.²⁰

Echocardiography

Before the investigation of clinical variables, the echocardiographic variables were analysed by one author through offline analysis using Image-Arena software (version 4.6; TomTec Imaging Systems, Unterschleissheim, Germany). The distance between the superior portion of the tricuspid septal leaflet insertion and the inferior portion of the medial insertion of the mitral valve on a typical apical four-chamber view was measured as the offset distance of the tricuspid valve septal leaflet (Fig 1). This offset distance was indexed by dividing by the body surface area. In addition, the offset distance of the tricuspid septal leaflet on a posterior-angulated apical view was measured and also indexed (Fig 1b). A measurement of an offset distance of the tricuspid valve inferior leaflet could not be taken because of the lack of stored appropriate images for it in many patients. The tricuspid valve annulus was measured as the distance between hinge points during diastole on an apical four-chamber view. The Z-score of the tricuspid valve annulus was calculated using the formula described by Pettersen et al.²¹ Tricuspid regurgitation was assessed as mild if the jet extended $<1/3$, moderate $>1/3$, and severe $>2/3$ of the way to the right atrial posterior wall according to the method in other study.⁵

Statistical analysis

All statistical analyses were performed using Statistical Package for the Social Sciences software (version 21.0; SPSS Korea Data Solutions, Seoul, Korea). The Kolmogorov-Smirnov test was used to evaluate the normal distribution of numerical variables, and according to the results of this test, the data were

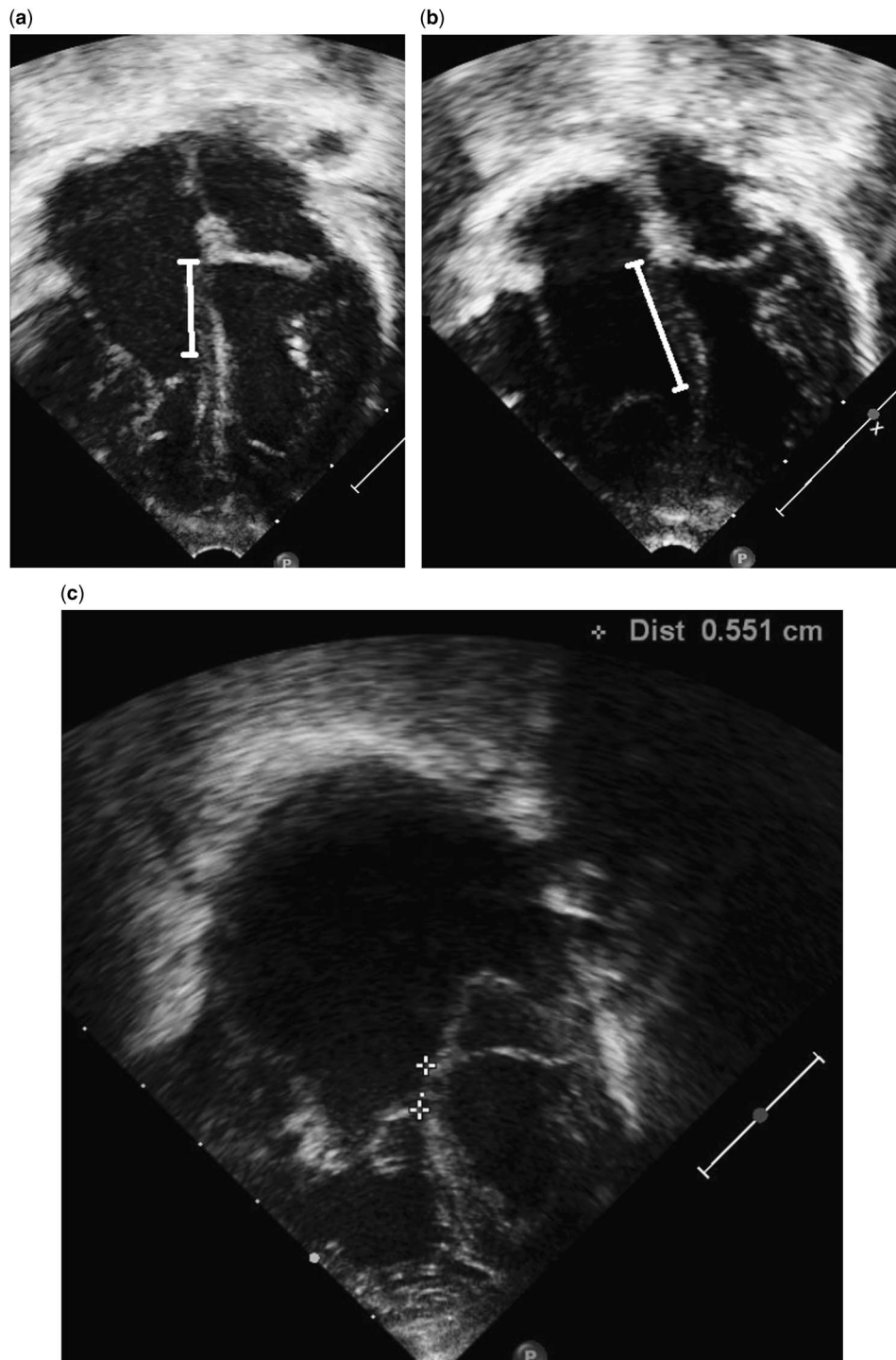


Figure 1.

A measurement of the offset distance of the tricuspid septal leaflet on a typical apical four-chamber view in a patient with Ebstein's anomaly (a); additional measurement of the offset distance on a posterior-angulated apical view in same patient (b); a measurement of the offset distance of the tricuspid septal leaflet in a patient with pulmonary atresia with intact ventricular septum. Indexed offset distance was 25.6 mm/m^2 (c).

presented as the mean \pm standard deviation or the median (range). Student's t-test, Mann-Whitney test, and χ^2 test were used for comparisons of variables between groups of patients. Wilcoxon signed rank

test was used for a comparison of offset distance indexes in respective groups. P-values < 0.05 were considered statistically significant. A receiver operational characteristic curve analysis was performed to

determine the optimal cut-off value for the diagnosis of Ebstein's anomaly.

A total of 14 echocardiographic images on an apical four-chamber view were randomly selected to determine the intra- and inter-observer variability in the measurements of the offset distance of the tricuspid septal leaflet. The intra-observer per cent precision was 12.7, and the inter-observer per cent precision was 18.3.

Results

Ebstein's anomaly versus pulmonary atresia with intact ventricular septum

The number of male patients in the Ebstein's anomaly group was 22 (39.3%), and in the pulmonary atresia with intact ventricular septum 42 (63.6%) (Table 1). Prenatal diagnosis was made more frequently in patients with Ebstein's anomaly than those with pulmonary atresia with intact ventricular septum ($p = 0.009$). Patients with Ebstein's anomaly were also born earlier ($p < 0.001$) and had significantly lower birth weights ($p = 0.006$) than patients with pulmonary atresia with intact ventricular septum (Table 1). Although the days after birth on which the echocardiographic examinations were conducted did not differ significantly between the two groups, the median height ($p = 0.007$), body weight ($p = 0.026$), and body surface area ($p = 0.015$) of the patients with pulmonary atresia with intact ventricular septum were significantly greater than those of the patients with Ebstein's anomaly (Table 1).

The median width of the tricuspid valve annulus and its Z-score in patients with Ebstein's anomaly

were significantly greater than those in patients with pulmonary atresia with intact ventricular septum ($p < 0.001$ for both parameters) (Table 1). The occurrence of more than moderate tricuspid regurgitation was more frequent ($p = 0.010$), and the peak velocity of tricuspid regurgitation in patients with pulmonary atresia with intact ventricular septum was significantly higher ($p < 0.001$) than those in patients with Ebstein's anomaly (Table 1). The median offset distance and the indexed offset distance of the tricuspid septal leaflet on a typical apical four-chamber view in patients with Ebstein's anomaly were significantly higher than those in patients with pulmonary atresia with intact ventricular septum (Table 1; Fig 2). Specifically, the median offset values in Ebstein's anomaly and pulmonary atresia with intact ventricular septum patients were 6.4 mm (with a range from 1.4 to 22.6 mm) and 1.5 mm (with a range from 0.0 to 5.5 mm), respectively, and the corresponding median-indexed offset distance values were 34.2 mm/m² (with a range from 7.1 to 119.1 mm/m²) and 7.2 mm/m² (with a range from 0.0 to 25.6 mm/m²), respectively ($p < 0.001$ for both parameters).

A receiver operational characteristic curve analysis of indexed offset distance was used to determine an optimal cut-off value for the diagnosis of Ebstein's anomaly. The area under the receiver operational characteristic curve was 0.970 with a 95% confidence interval of 0.941–0.999 (Fig 3). When the cut-off value of 8 mm/m² was applied to differentiate Ebstein's anomaly from pulmonary atresia with intact ventricular septum, the sensitivity was 96.3%, but the specificity was only 56.1%. The receiver operational characteristic curve analysis indicated that the

Table 1. The demographic, anthropometric, and echocardiographic characteristics of the 56 patients with Ebstein's anomaly and 66 patients with pulmonary atresia with intact ventricular septum (PAIVS) included in the study.

	Ebstein's anomaly (n = 56)	PAIVS (n = 66)	p-value
Number of males	22 (39.3%)	42 (63.6%)	0.007
Prenatal diagnosis	46 (82.1%)	40 (60.6%)	0.009
Gestational age (weeks)	37.9 (30.6–40.1)	38.7 (26.4–41.0)	0.001
Birth weight (kg)	2.81 ± 0.53	3.09 ± 0.56	0.006
Days after birth (of examination)	1 (1–30)	2 (1–28)	0.555
Height (cm)	48.03 ± 3.06	49.52 ± 2.94	0.007
Weight (kg)	2.87 ± 0.54	3.09 ± 0.56	0.026
Body surface area (m ²)	0.19 ± 0.02	0.20 ± 0.02	0.015
Offset distance (mm)	6.4 (1.4–22.6)	1.5 (0.0–5.5)	<0.001
Offset distance index (mm/m ²)	34.2 (7.1–119.1)	7.2 (0.0–25.6)	<0.001
Tricuspid annulus (mm)	16.63 ± 3.93	9.44 ± 2.84	<0.001
Tricuspid annulus (Z-score)	1.38 ± 1.31	-1.78 ± 1.56	<0.001
Tricuspid regurgitation			0.010
Absent/mild	26 (46.4%)	16 (24.2%)	
Moderate/severe	30 (53.6%)	50 (75.8%)	
Peak velocity (m/s)	2.97 ± 0.75	4.59 ± 1.07	<0.001

Data are represented as the number (frequency), the median (range), or the mean ± SD

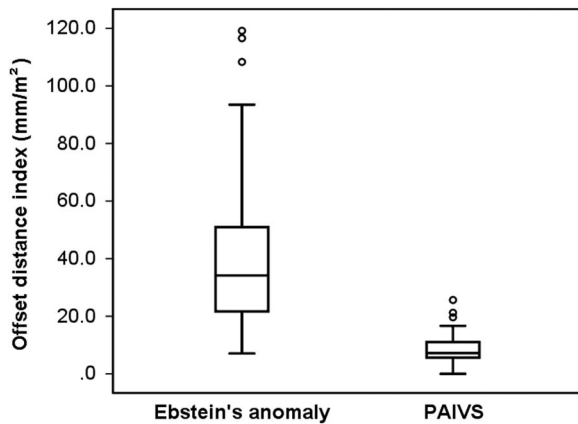


Figure 2.
A box-and-whisker plot showing the offset distance index of the tricuspid septal leaflet in the Ebstein's anomaly and pulmonary atresia with intact ventricular septum groups.

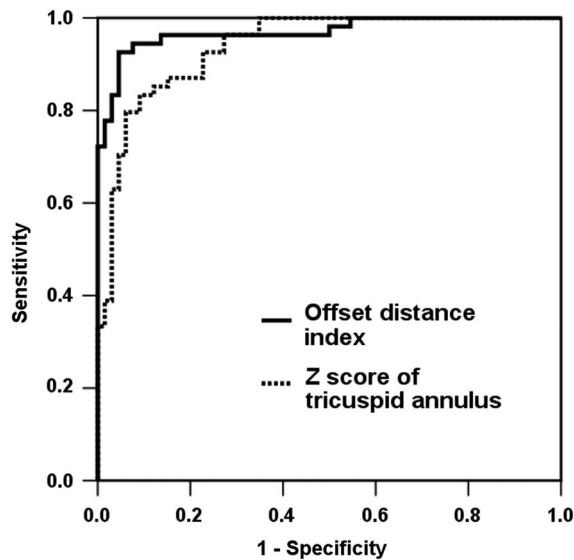


Figure 3.
Receiver operating characteristic curve analysis of the offset distance index of the tricuspid septal leaflet and Z-score of width of the tricuspid annulus on a typical apical four-chamber view for the discrimination of Ebstein's anomaly and pulmonary atresia with intact ventricular septum in neonatal patients.

optimal indexed offset distance cut-off value was 13.9 mm/m^2 , which corresponded to a sensitivity of 94.4% and a specificity of 92.4%. Additional receiver operational characteristic curve analysis of Z-score of the tricuspid annulus was performed. The area under the receiver operational characteristic curve was 0.939, with a 95% confidence interval of 0.899–0.978 (Fig 3). The optimal Z-score of the tricuspid annulus was -0.32 , which corresponded to a sensitivity of 87.0% and a specificity of 84.8%.

The offset distance on the posterior-angulated apical view could be measured in 39 (69.6%) of

the 56 patients with Ebstein's anomaly; the median distance was 9.7 mm (with a range from 4.6 to 33.2 mm). This distance was divided by the body surface area to generate the indexed value; the median-indexed offset distance on the posterior-angulated apical view was 54.5 mm/m^2 (with a range from 23.7 to 202.1 mm/m^2), which was significantly greater than the median-indexed offset distance on the typical apical four-chamber view in the Ebstein's anomaly group ($p < 0.001$). The offset distance on the posterior-angulated apical view could be measured in 28 (42.4%) of the 66 patients with pulmonary atresia with intact ventricular septum; the median distance was 2.6 mm (with a range from 0.6 to 6.4 mm). The median-indexed offset distance on the posterior-angulated apical view was 13.7 mm/m^2 (with a range from 5.6 to 29.8 mm/m^2), which was significantly greater than the median-indexed offset distance on the typical apical four-chamber view in the pulmonary atresia with intact ventricular septum group ($p < 0.001$).

Comparisons of subgroups of patients with pulmonary atresia with intact ventricular septum

Of the 66 patients with pulmonary atresia with intact ventricular septum, 29 (43.9%) had an indexed offset distance $\geq 8 \text{ mm/m}^2$. The other clinical and echocardiographic characteristics examined did not differ significantly between these 29 patients and the remaining 37 patients in the pulmonary atresia with intact ventricular septum group, except Z-score of the tricuspid annulus (Table 2).

Follow-up of patients

The median follow-up durations were 1.6 years (with a range from 0.0 to 10.6 years) for patients with Ebstein's anomaly and 3.4 years (with a range from 0.0 to 12.9 years) for patients with pulmonary atresia with intact ventricular septum. During the follow-up period, 23 (41.1%) patients with Ebstein's anomaly and 49 (74.2%) patients with pulmonary atresia with intact ventricular septum underwent surgical management; however, no changes to the echocardiographic diagnoses were made. Of the patients, 12 with Ebstein's anomaly died during follow-up, in whom five patients were complicated by pulmonary atresia, and three patients with pulmonary atresia with intact ventricular septum died during follow-up, two of whom had an indexed offset distance value greater than 8 mm/m^2 .

Discussion

The aim of this study was to examine the validity of the commonly used 8 mm/m^2 cut-off value of the

Table 2. Comparisons between two subgroups of patients with pulmonary atresia with intact ventricular septum, categorised according to their offset-I value.

	Offset distance index		p-value
	<8 mm/m ² (n = 37)	≥8 mm/m ² (n = 29)	
Number of males	24 (64.9%)	18 (62.1%)	0.815
Prenatal diagnosis	23 (62.2%)	17 (58.6%)	0.770
Gestational age (weeks)	38.9 (26.4–41.0)	38.7 (35.3–40.0)	0.581
Birth weight (kg)	3.10 ± 0.61	3.08 ± 0.49	0.927
Days after birth (of examination)	2 (1–27)	2 (1–28)	0.745
Height (cm)	49.68 ± 3.36	49.32 ± 2.33	0.613
Weight (kg)	3.13 ± 0.62	3.05 ± 0.50	0.579
Body surface area (m ²)	0.20 ± 0.03	0.19 ± 0.02	0.595
Offset distance (mm)	1.2 (0.0–1.7)	2.2 (1.3–5.5)	<0.001
Offset distance index (mm/m ²)	5.77 (0.0–7.73)	11.4 (8.3–25.6)	<0.001
Tricuspid annulus (mm)	8.83 ± 2.51	10.20 ± 3.07	0.057
Tricuspid annulus (Z-score)	-2.13 ± 1.49	-1.34 ± 1.55	0.041
Tricuspid regurgitation			0.240
Absent/mild	11 (29.7%)	5 (17.2%)	
Moderate/severe	26 (70.3%)	24 (82.8%)	
Peak velocity (m/s)	4.66 ± 0.98	4.51 ± 1.17	0.617

Data are represented as the number (frequency), the median (range), or the mean ± SD

indexed offset distance of the tricuspid septal leaflet for the diagnosis of Ebstein's anomaly in neonatal populations. A receiver operational characteristic curve analysis suggested that ≥ 13.9 mm/m² is a more appropriate indexed offset distance cut-off than ≥ 8 mm/m². However, the range of indexed offset distance values in the 56 patients with Ebstein's anomaly overlapped with the range of indexed offset distance values in the 66 patients with pulmonary atresia with intact ventricular septum; therefore, we were unable to determine an indexed offset distance value that allowed a confirmative diagnosis of Ebstein's anomaly in the population studied. These results are in common with the findings of Gussenhoven et al,¹⁹ who reported an overlap between the ranges of the offset distances of the tricuspid septal leaflet measured on a typical apical four-chamber view in patients with Ebstein's anomaly and normal controls.

Echocardiographic measurements of the offset distance of the tricuspid septal leaflet in normal healthy neonates have only been made in a limited number of patients.^{18,19} Although Shiina et al¹⁸ reported 0–6.3 mm/m² as the normal indexed range, the age range of the 30 patients included in the study was very wide (4 days to 66 years), and the number of neonates was not specified. Gussenhoven et al¹⁹ reported that the offset distance of the tricuspid septal leaflet was ≤ 7 mm in 20 normal neonates. In addition, Vettrano et al²² reported a range from 2.2 to 6.9 mm in normal third trimester fetuses. We assume that the upper limit of the indexed offset distance value in normal neonates may be above

8 mm/m² when considering the typical range of body surface areas of neonates. Additional measurements of the indexed offset distance value of the tricuspid septal leaflet in normal neonates are required to examine this assumption further.

During this study, we were initially concerned about the possibility of a misdiagnosis of Ebstein's anomaly in patients with pulmonary atresia with intact ventricular septum. However, the clinical and echocardiographic variables of the two subgroups of pulmonary atresia with intact ventricular septum patients separated on the basis of their indexed offset distance value (<8 and ≥ 8 mm/m²) were comparable, except Z-score of the tricuspid annulus. In addition, only 6.9% (2/29) of the patients in the subgroup of pulmonary atresia with intact ventricular septum patients with an indexed offset distance value ≥ 8 mm/m² died during follow-up. In comparison, 71.4% (5/7) of the patients with Ebstein's anomaly and pulmonary atresia died during follow-up. Z-score of the tricuspid annulus in a subgroup of pulmonary atresia with intact ventricular septum with offset distance index ≥ 8 mm/m² was greater than in other subgroup. This relationship was an unexpected finding because patients with Ebstein's anomaly simultaneously were excluded from the group of pulmonary atresia with intact ventricular septum in this study, and implicate a difficulty of diagnostic exclusion of Ebstein's anomaly in a part of patients with pulmonary atresia with intact ventricular septum. Morphologic classification based on right ventricular cavity size was carried out in the hearts with pulmonary atresia with intact ventricular septum from

a prognostic viewpoint.²³ Moreover, Z-score of the tricuspid valve has been known as a parameter of right ventricular size and as an important predictor of biventricular repair.²⁴ However, its differential diagnostic usefulness in this study seems to be not superior to offset distance of the tricuspid septal leaflet.

Basic intrinsic morphologic feature of Ebstein's anomaly is the displacement of the septal and inferior leaflet attachments, and the point of maximum displacement is at the commissure between these two leaflets.²⁵ Therefore, in accordance with this intrinsic feature, it is well known that the maximal offset distance of the tricuspid septal leaflet can be measured in the posterior-angulated apical view in patients with this malformation.¹⁹ Here, the median-indexed offset distance on the posterior-angulated apical view was significantly longer than the median-indexed offset distance on the typical apical four-chamber view in patients with Ebstein's anomaly. Despite this finding, we cannot conclude with certainty that it will be possible to determine a cut-off value of indexed offset distance on the posterior-angulated apical view that will allow a definite diagnosis of Ebstein's anomaly. In patients with pulmonary atresia with an intact ventricular septum, indexed offset distance on the posterior-angulated view, which was also longer than that on the typical apical four-chamber view, had overlapped range with the range of indexed offset distance on the posterior-angulated view in patients with Ebstein's anomaly.

The displacement of inferior leaflet of the tricuspid valve that could not be measured in this study has also been used in the diagnosis of Ebstein's anomaly. We think that it would be helpful in a definitive diagnosis of Ebstein's anomaly. Rusconi et al²⁶ reported that the distal edge of inferior leaflet was attached in a linear manner to the ventricular wall in their 15 cases but one of these. Recently, a new method for evaluating tricuspid valve displacement in which displacements of anterior/inferior tricuspid leaflets are additionally assessed for a diagnosis of Ebstein's anomaly was suggested.²⁷ We think that this new method may support a more reliable diagnosis of Ebstein's anomaly in clinical practice.

There are several limitations in this study. The offset distance of the tricuspid septal leaflet on the posterior-angulated apical view could not be measured in all patients, and we are not confident that the measured values are the largest value in individual patient. Moreover, the offset distance of the tricuspid inferior leaflet could not be measured. In addition, there were significant differences of demographic/anthropometric variables between two groups; however, we think that they might not be the fatal limitations of this study because the measured value

of offset distance of tricuspid septal leaflet was indexed by body surface area.

In conclusion, this study indicates that an indexed offset distance cut-off ≥ 8 mm/m² cannot be used for the diagnosis of complicated Ebstein's anomaly in neonatal patients with pulmonary atresia with intact ventricular septum. More extensive prospective echocardiographic or autopsy studies are required to determine a more appropriate diagnostic cut-off for the offset distance of the tricuspid septal leaflet in neonatal populations.

Acknowledgements

None.

Financial Support

This research received no specific grant from any funding agency, commercial or not-for-profit sectors.

Conflicts of Interest

None.

Ethical Standard

The Investigational Review Board of Asan Medical Center approved this retrospective study (2014-0052) and waived the need for patient consent.

References

- Dearani JA, Danielson GK. Congenital heart surgery nomenclature and database project: Ebstein's anomaly and tricuspid valve disease. *Ann Thorac Surg* 2000; 69: S106-S117.
- Celermajer DS, Bull C, Till JA, et al. Ebstein's anomaly: presentation and outcome from fetus to adult. *J Am Coll Cardiol* 1994; 23: 170-176.
- Yetman AT, Freedom RM, McCrindle BW. Outcome in cyanotic neonates with Ebstein's anomaly. *Am J Cardiol* 1998; 81: 749-754.
- Jaquiss RDB, Imamura M. Management of Ebstein's anomaly and pure tricuspid insufficiency in the neonate. *Semin Thorac Cardiovasc Surg* 2007; 19: 258-263.
- Wald RM, Adatia I, Van Arsdell GS, Hornberger LK. Relation of limiting ductal patency to survival in neonatal Ebstein's anomaly. *Am J Cardiol* 2005; 96: 851-856.
- Oxenius A, Attenhofer Jost CH, Prêtre R, et al. Management and outcome of Ebstein's anomaly in children. *Cardiol Young* 2012; 15: 1-8.
- Yu JJ, Yun TJ, Won HS, et al. Outcome of neonates with Ebstein's anomaly in the current era. *Pediatr Cardiol* 2013; 34: 1590-1596.
- Dyamenahalli U, McCrindle BW, McDonald C, et al. Pulmonary atresia with intact ventricular septum: management of, and outcomes for, a cohort of 210 consecutive patients. *Cardiol Young* 2004; 14: 299-308.
- Daubeney PEF, Wang D, Delany DJ, et al. Pulmonary atresia with intact ventricular septum: predictors of early and medium-term outcome in a population-based study. *J Thorac Cardiovasc Surg* 2005; 130: 1071-1078.

10. Kobza R, Kurz DJ, Oechslin EN, et al. Aberrant tendinous chords with tethering of the tricuspid leaflets: a congenital anomaly causing severe tricuspid regurgitation. *Heart* 2004; 90: 319–323.
11. Attenhofer Jost CH, Connolly HM, Dearani JA, Edwards WD, Danielson GK. Ebstein's Anomaly. *Circulation* 2007; 115: 277–285.
12. Kapusta L, Eveleigh RM, Poulino SE, et al. Ebstein's anomaly: factors associated with death in childhood and adolescence: a multi-centre, long-term study. *Eur Heart J* 2007; 28: 2661–2666.
13. Paranon S, Acar P. Ebstein's anomaly of the tricuspid valve: from fetus to adult. *Heart* 2008; 94: 237–243.
14. Chang YM, Wang JK, Chiu SN, et al. Clinical spectrum and long-term outcome of Ebstein's anomaly based on a 26-year experience in an Asian cohort. *Eur J Pediatr* 2009; 168: 685–690.
15. Boston US, Goldberg SP, Ward KE, et al. Complete repair of Ebstein anomaly in neonates and young infants: a 16-year follow-up. *J Thorac Cardiovasc Surg* 2011; 141: 1163–1169.
16. Muraru D, Badano LP, Sarais C, Soldà E, Iliceto S. Evaluation of tricuspid valve morphology and function by transthoracic three-dimensional echocardiography. *Curr Cardiol Rep* 2011; 13: 242–249.
17. Krieger EV, Valente AM. Diagnosis and management of Ebstein anomaly of the tricuspid valve. *Curr Treat Options Cardiovasc Med* 2012; 14: 594–607.
18. Shiina A, Seward JB, Edwards WD, Hagler DJ, Tajik AJ. Two-dimensional echocardiographic spectrum of Ebstein's anomaly: detailed anatomic assessment. *J Am Coll Cardiol* 1984; 3: 356–370.
19. Gussenhoven EJ, Stewart PA, Becker AE, Essed CE, Lightvoet KM, De Villeneuve VH. 'Offsetting' of the septal tricuspid leaflet in normal hearts and in hearts with Ebstein's anomaly. *Am J Cardiol* 1984; 53: 172–176.
20. Haycock GB, Schwartz GJ, Wisotsky DH. Geometric method for measuring body surface area: a height-weight formula validated in infants, children, and adults. *J Pediatr* 1978; 93: 62–66.
21. Pettersen MD, Du W, Skeens ME, Humes RA. Regression equations for calculation of z scores of cardiac structures in a large cohort of healthy infants, children, and adolescents: an echocardiographic study. *J Am Soc Echocardiogr* 2008; 21: 922–934.
22. Vetraino IM, Huang R, Cornstock CH. The normal offset of the tricuspid septal leaflet in the fetus. *J Ultrasound Med* 2002; 21: 1099–1104.
23. Choi YH, Seo JW, Choi JY, Yun YS, Kim SH, Lee HJ. Morphology of tricuspid valve in pulmonary atresia with intact ventricular septum. *Pediatr Cardiol* 1998; 19: 381–389.
24. Hanley FL, Sade RM, Blackstone EH, Kirklin JW, Freedom RM, Nanda NC. Outcomes in neonatal pulmonary atresia with intact ventricular septum. A multiinstitutional study. *J Thorac Cardiovasc Surg* 1993; 105: 406–423.
25. Anderson KR, Zuberbuhler JR, Anderson RH, Becker AE, Lie JT. Morphologic spectrum of Ebstein's anomaly of the heart. *Mayo Clin Proc* 1979; 54: 174–180.
26. Rusconi PG, Zuberbuhler JR, Anderson RH, Rigby ML. Morphologic-echocardiographic correlates of Ebstein's malformation. *Eur Heart J* 1991; 12: 784–790.
27. Jiang GP, Gao LC, Gong FQ, He J, Ye JJ. A new method for evaluating tricuspid valve displacement in children with Ebstein's anomaly: using the annulus and coronary sinus as a reference point. *Pediatr Cardiol* 2014; 35: 270–275.